

Antidiarrheal and antioxidative capability of synbiotic yogurt to the rats

^{1*}Rahayu, W. P., ¹Astawan, M., ²Wresdiyati, T. and ¹Mariska, S.

¹Department of Food Science and Technology, Faculty of Agricultural Technology and Engineering, Bogor Agricultural University, Campus IPB Darmaga, PO Box 220, Bogor 16002, Indonesia

²Department of Anatomy, Physiology, and Pharmacology, Faculty of Veterinary Medicine, Bogor Agricultural University, Indonesia

Article history

Received: 27 October 2011
Received in revised form:
21 September 2012
Accepted: 21 September 2012

Abstract

The objective of this research was to utilize the local probiotic lactic acid bacteria, isolated from beef in some traditional markets in Bogor (*L. plantarum* 2C12 and *L. fermentum* 2B4), in synbiotic yogurt making and analyzing its antidiarrheal and antioxidative capability in rat models. The rats were treated with synbiotic yogurt and enteropathogenic *Escherichia coli* (EPEC) intervention. The antidiarrheal parameters were the appearance and the gravimetrically water content of the rats' feces. The normal feces was round or oval, black, and hard or soft with lower fecal water content. The diarrheal feces was not round nor oval, liquid or unformed, brownish, and soft or slimy with higher fecal water content. The antioxidative parameter was immunohistochemically superoxide dismutase (SOD) content in liver and kidney tissues, shown by brown color in nucleus. This synbiotic yogurt showed antibacterial and antidiarrheal activities in the rat's model. This research shown that the feces of the rats, which were infected by EPEC and treated by synbiotic yogurt contained *L. fermentum* 2B4 was normal, specifically oval, black, and soft feces. Whereas, the rats which were infected by EPEC, but were not treated by the synbiotic yogurt shown the diarrheal feces. The synbiotic yogurt also had antioxidative effect. For 21 days treatment with synbiotic yogurt to the EPEC intervention rats, the Cu, Zn-SOD content in the liver and kidney increased, 17.72 and 24.96% respectively higher than the rats that were not treated with it.

Keywords

Yogurt
probiotic
antioxidants
antimicrobial agents

© All Rights Reserved

Introduction

Human gastrointestinal tract is a tube that is rolled over approximately 9 m through the center of the body. The human gastrointestinal tract has a surface area about 300 m² (Loo, 2006). Large surface allows the organ contacts with food during the digestive process. One cause of diarrheal is bacterial infection in the intestine, such as bacterial infection from enteropathogenic *E. coli* (EPEC). Budiarti (1997) reported that EPEC was one major cause of children diarrheal in Indonesia which the prevalence reached 55%. Therefore, the prevention and control of diarrheal is very important. EPEC infection can also cause oxidative stress and affect the other organs. It is because blood from the intestine flows to the other organs such as liver and kidney. Liver detoxification function is processing of hazardous substances into harmless substances which then will be removed by the kidney. *E. coli* strain can cause extraintestinal

infection such as urinary tract infection, include kidney infection. Those infections can be prevented by maintaining the digestive microorganisms in the balance composition. To stimulate the growth of healthy bacteria and reduce the amount of harmful microbes, one that human can do is eating probiotic and prebiotic products regularly (Loo, 2006).

Therefore, the aim of this research was to apply the two local probiotic lactic acid bacteria isolated from beef in some traditional markets in Bogor (*L. plantarum* 2C12 and *L. fermentum* 2B4) for the production of synbiotic yogurt. Furthermore, the antidiarrheal and antioxidative properties of the synbiotic yogurt were analyzed (*in vivo*).

Materials and Methods

The bacteria for yogurt formulas were: *Lactobacillus bulgaricus*, *Streptococcus thermophilus*, and local probiotic lactic acid bacteria

*Corresponding author.
Email: wini_a@hotmail.com

isolated from beef in some traditional markets in Bogor (*L. plantarum* 2C12 and *L. fermentum* 2B4). The enteropathogenic bacteria was *Escherichia coli* K1.1 (EPEC K1.1). Media cultures were: de man rogosa sharpe broth (MRSB) (Oxoid), de man rogosa sharpe agar (MRSA) (Oxoid), nutrient broth (NB) (Oxoid), eosin methylene blue agar (EMBA) (Difco), KH_2PO_4 , aquadest, NaOH 1N, glucose, bacto agar (Difco), CaCO_3 , skim milk, sugar, fructooligosaccharide (FOS), and alcohol 70%. The rats used in this research were 70 male albino Sprague Dawley rats, 80-100 g of body weight. The rats were obtained from biofarmaka research center, Bogor. The materials used for analyzing antidiarrheal and antioxidative properties were: rats feed (casein, corn oil, carboxymethylcellulose, mineral mix, vitamin mix, cornstarch, and water), liver and kidney of rats, bouin solution (saturated picrate acid, 37–40% formalin, and glacial acetic acid with a ratio of 15 : 5 : 1), 70, 80, 90, 95, and 100% (absolute) alcohol, xylol, paraffin, aquadest, NaCl crystal, physiological solution of 0.9% NaCl, toluene, neophrene, tap water, $\text{Na}_2\text{HPO}_4 \cdot 12\text{H}_2\text{O}$, $\text{NaH}_2\text{PO}_4 \cdot 2\text{H}_2\text{O}$, phosphate buffered saline (PBS), aquabidest, methanol, H_2O_2 , normal serum, Cu, Zn-SOD primary antibody (Sigma S2147), dako envision system peroxidase (Dako K1491) as a secondary antibody, diamin benzidine solution (DAB) as a chromogen, haematoxylin, and entellan.

Determination of synbiotic yogurt formula

There were four yogurt formulas made: Formula 1 (F1): *L. bulgaricus* + *S. thermophilus*; formula 2 (F2): *L. bulgaricus* + *S. thermophilus* + *L. plantarum* 2C12; formula 3 (F3): *L. bulgaricus* + *S. thermophilus* + *L. fermentum* 2B4, and formula 4 (F4): *L. bulgaricus* + *S. thermophilus* + *L. plantarum* 2C12 + *L. fermentum* 2B4. Yogurt-making process began by dissolving 5% sugar, 5% FOS as a prebiotic, and skim milk in order to reach the total solids of yogurt to 22%. After that, the mixture was heated at temperature of 85 °C for 3 minutes and then it was cooled to 37°C. Afterwards, the starter (2%) was added. Furthermore, the mixture was incubated at 37°C for 24 hours and kept cold at a temperature of 5-6°C.

Antibacterial activity of synbiotic yogurt (Davidson et al., 2005)

The antibacterial activity analysis of synbiotic yogurt was done by contact method in the EMBA medium. EPEC bacteria as much as 0.1 mL (1%) were contacted with 10 mL of each yogurt formula for 2, 4, and 6 hours and incubated at 37°C for 48 hours. After the incubation, the number of EPEC bacteria at the

Table 1. The groups of rats according to the given treatments

No.	Rats Group	Treatment
1.	Negative control: 15 rats	Normal rats that were fed with standard feed and aquadest
2.	Synbiotic yogurt: 15 rats	The rats that were fed with standard feed and synbiotic yogurt
3.	Synbiotic yogurt + EPEC: 15 rats	The rats that were fed with standard feed and synbiotic yogurt, but interspersed with EPEC intervention
4.	Positive control: 15 rats	The rats that were fed with standard feed and EPEC intervention
5.	Standard yogurt: 5 rats	The rats that were fed with standard feed and standard yogurt

Notes:

The synbiotic yogurt was the best yogurt formula (F3).

Standard yogurt was the yogurt containing *L. bulgaricus*, *S. thermophilus* and the prebiotic FOS. Yogurt was administered orally as much as 1 mL per day (LAB population of 10^6 CFU mL^{-1}) using the sonde from day 1 (the beginning of the treatment) until day 21 (the end of the treatment).

EPEC intervention (caused diarrheal) was given orally using the sonde as much as 1 mL per day with a population of 10^7 CFU mL^{-1} for 7 days (day 8 to day 14).

end of each contact time was calculated based on a BAM method (2001). The decrease number of EPEC is the number of EPEC in the beginning minus the number of EPEC at the end of contact time (notes: all in units of log CFU mL^{-1}).

Antidiarrheal and antioxidative properties of synbiotic yogurt

The 70 rats were divided into five groups (Table 1). Baseline group represented the initial condition of the rats before the treatments (yogurt samples and/or injection EPEC treatments) began. Therefore, this baseline group consisted of five rats and dissected after the period of adaptation. The weight of each rat was weighed every three days and, the fecal were taken from each rat on day 20, observed the shape, color, and the softness level. Fecal water content was also analyzed (Wrolstad et al., 2005). The antioxidant superoxide dismutase (SOD) content in liver and kidney of rats was analyzed immunohistochemically (Kiernan, 1990; Wresdiyati et al., 2002). The liver/kidney of rats were washed with 0.9% physiological NaCl and fixed in bouin solution for 24 hours. Afterwards, these were processed using paraffin to obtain tissue blocks and sliced with a thickness of 4 μm using rotary microtome. Furthermore, the incision was placed on the object glass coated with neophrene in toluene (neophrene: toluene = 0.2 mL:1.8 mL), stained by diamin benzidine solution (DAB) with immunohistochemical staining technique (Kiernan, 1990; Wresdiyati et al., 2002). The observations on cells producing Cu, Zn-SOD were held by comparing the intensity of brown color that appeared in tissue preparations observed. The differences in intensity of color formed were divided into positive and negative reactions. Brown color indicated a positive reaction

to the antioxidant Cu, Zn-SOD. The darker of brown color in the liver/kidney tissues means the higher content of antioxidant Cu, Zn-SOD. Furthermore, quantitative observations were held by counting the number of nucleus at various intensity of brown coloring some areas of view of the preparations and the results were statistically analyzed by analysis of variance (Anova) and Duncan multiple range tests.

Results

The best synbiotic yogurt formula

The antimicrobial activity of yogurts can be seen in Table 2. The decrease number of EPEC of the four yogurt formulas were not significantly different ($p > 0.05$) after 2, 4, and 6 hours contact. Similar to the log reduction value of EPEC, the acidity (pH value) of each yogurt formula was also not significantly different ($p > 0.05$), ranging from 4.11 to 4.84. Yogurt F3 had the best appearance because the whey produced was relatively little and stable (not separated). The yogurt was almost similar to yogurt in the market, thus in the future it will need less food additives (e.g. stabilizer) relatively to improve its appearance. Therefore, it was chosen for further study.

Feces appearance and water content

The rats began to have diarrheal on day 6 after the first EPEC infection. The feces appearance (shape, color, and softness of the feces) of rats group treated by the synbiotic yogurt + EPEC intervention was classified to the normal feces (oval, black, and soft feces) while the group treated by EPEC intervention was classified to the diarrheal (not round nor oval, brownish, and soft feces). The fecal water content of positive control group was significantly ($p < 0.05$) higher (66.87%) than that of negative control group (55.94%) and the group treated by synbiotic yogurt (56.01%). The higher fecal water content indicated the diarrheal rat and it was found in the rats treated by EPEC intervention. This means that EPEC infection without synbiotic yogurt could cause diarrheal.

Antioxidant SOD content in liver tissue

The example of immunohistochemical staining of antioxidant SOD in rats liver tissue could be seen in Figure 1, while the quantitative observation on the liver cell nucleus or hepatocyte at the terminations (rat dissection) on day 8, 15, and 21 are presented in Table 3. Termination on day 8 showed that all groups had similar antioxidant Cu, Zn-SOD content ($p > 0.05$). Termination on day 15 showed that the group treated by the synbiotic yogurt had the highest Cu, Zn-SOD content. It was proved by the number of

Table 2. Antibacterial activity of yogurt

Yogurt Formula	The Decrease Number of EPEC (log CFU mL ⁻¹)		
	Contact tests (hours)		
	2	4	6
F1	2.78 ± 0.54 ^a	3.02 ± 0.25 ^a	3.98 ± 0.26 ^a
F2	2.73 ± 0.23 ^a	3.15 ± 0.50 ^a	4.07 ± 0.48 ^a
F3	2.69 ± 0.30 ^a	3.54 ± 0.38 ^a	4.31 ± 0.88 ^a
F4	2.51 ± 0.72 ^a	3.61 ± 0.23 ^a	4.19 ± 0.43 ^a

Notes:

F1 = yogurt formula contained *L. bulgaricus*, *S. thermophilus*, and FOS.

F2 = yogurt formula contained *L. bulgaricus*, *S. thermophilus*, *L. plantarum* 2C12, and FOS.

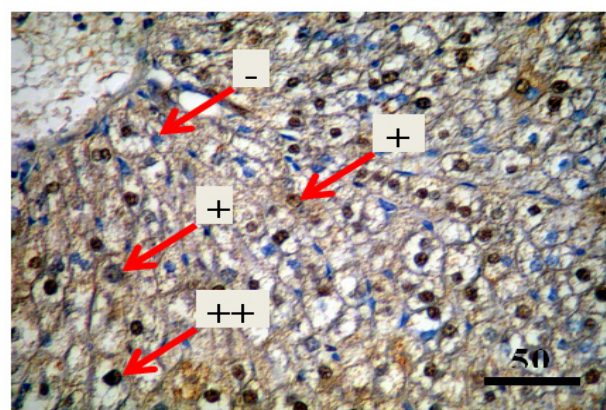
F3 = yogurt formula contained *L. bulgaricus*, *S. thermophilus*, *L. fermentum* 2B4, and FOS.

F4 = yogurt formula contained *L. bulgaricus*, *S. thermophilus*, *L. plantarum* 2C12, *L.*

fermentum 2B4, and FOS.

The data were analyzed statistically (by Anova and Duncan tests) in every same column of the table.

The values followed by the same letters indicated those were not significantly different ($p > 0.05$).



Notes:

+++ : strong positive (dark brown), ++ : moderate positive (medium brown), + : weak positive (brown mixed with blue), - : negative (blue).

Figure 1. Photomicrograph of the rat liver tissue

hepatocyte (in the rats group treated by the synbiotic yogurt) with strong positive reaction was significantly ($p < 0.01$) the highest compared to the other groups. Thus, the synbiotic yogurt could increase the content of antioxidant Cu, Zn-SOD in the liver tissue. The termination on day 15 also shown that the positive control group, which received the EPEC intervention treatment, contained a high Cu, Zn-SOD content as well. It was presented by the number of hepatocyte (in positive control group) with strong positive reaction (59.67 hepatocytes) was not significantly different ($p > 0.05$) compared to the group treated by the synbiotic yogurt (63.00 hepatocytes). The termination on day 22 shown that positive control group had significantly lower value than that the synbiotic yogurt group.

Antioxidant SOD content in kidney tissue

The quantitative observation of the amount of nucleus in the renal tubule cells that contained Cu, Zn-SOD, at the terminations on day 8, 15, and 22 are presented in Table 4. Termination on day 8 shown that the synbiotic yogurt group and synbiotic yogurt + EPEC group, which was just treated by the synbiotic

Table 3. The average number of liver cell nucleus at a variety levels of Cu, Zn-SOD content in rats liver tissue at the termination on day 8, 15, and 22 per area of view with a magnification of 200x

The Number of Rats Liver Cell Nucleus				
Termination on	+++	++	+	-
Day 8				
Base line	36.00 ± 6.24 ^{ab}	39.33 ± 3.06 ^a	20.00 ± 2.64 ^a	25.00 ± 3.60 ^c
Negative control	48.67 ± 2.08 ^d	43.00 ± 5.00 ^{ab}	22.33 ± 3.21 ^a	21.33 ± 2.08 ^{bc}
Synbiotic yogurt	46.33 ± 2.89 ^{cd}	48.67 ± 4.04 ^b	18.67 ± 2.52 ^a	24.67 ± 3.06 ^{bc}
Synbiotic yogurt + EPEC	40.67 ± 3.51 ^{bc}	41.00 ± 4.58 ^a	27.00 ± 1.00 ^a	14.00 ± 3.60 ^a
Positive control	32.67 ± 2.08 ^a	37.67 ± 3.06 ^a	28.33 ± 6.81 ^a	18.00 ± 3.60 ^{ab}
Termination on Day 15				
Negative control	43.33 ± 5.13 ^a	36.67 ± 1.53 ^a	22.67 ± 1.53 ^b	33.00 ± 5.29 ^b
Synbiotic yogurt	63.00 ± 3.60 ^b	46.33 ± 3.51 ^b	15.00 ± 1.73 ^a	13.33 ± 5.13 ^a
Synbiotic yogurt + EPEC	32.67 ± 1.53 ^a	35.33 ± 1.15 ^a	14.00 ± 2.00 ^a	48.33 ± 2.52 ^c
Positive control	59.67 ± 7.23 ^b	36.67 ± 1.53 ^a	12.33 ± 3.78 ^a	23.33 ± 6.81 ^{ab}
Termination on Day 22				
Negative control	43.00 ± 4.36 ^{ab}	45.67 ± 5.86 ^b	34.67 ± 2.52 ^c	17.67 ± 2.08 ^a
Synbiotic yogurt	66.00 ± 5.20 ^c	43.00 ± 1.00 ^b	15.33 ± 5.13 ^{ab}	18.67 ± 5.69 ^a
Synbiotic yogurt + EPEC	43.67 ± 1.53 ^{ab}	36.00 ± 2.00 ^b	18.67 ± 1.53 ^b	21.33 ± 5.03 ^a
Positive control	36.67 ± 1.53 ^a	26.33 ± 8.14 ^a	11.33 ± 3.78 ^a	41.00 ± 2.00 ^c
Standard yogurt	48.00 ± 5.29 ^b	37.33 ± 1.53 ^b	12.67 ± 3.06 ^{ab}	33.67 ± 3.06 ^b

Notes:

The data were analyzed statistically (by Anova and Duncan tests) in every same column and termination time of the table. The values followed by the same letters indicated those were not significantly different ($p > 0.05$).

yogurt on day 1 to day 7, contained the higher Cu, Zn-SOD ($p < 0.01$) than the negative control and positive control groups, which did not receive the synbiotic yogurt.

Discussion

The decrease number of EPEC of the four yogurt formulas was caused by activity of the bacteria. According to Songisepp *et al.* (2004), *L. fermentum* had antimicrobial activity against EPEC, *Staphylococcus aureus*, *Salmonella Typhimurium*, *S. Enteritidis*, and *Shigella sonnei*. The high antimicrobial activity of *L. fermentum* was associated with the production and synergistic activity of the organic acids and H_2O_2 . The organic acids and H_2O_2 could inhibit the growth of pathogenic bacteria. In

Table 4. The average number of renal tubules nucleus at a variety levels of Cu, Zn-SOD content in rats kidney tissue at the termination on day 8, 15, and 22 per area of view with a magnification of 200x

Termination on Day 8	The Number of Rats Renal Tubules Nucleus			
	+++	++	+	-
Baseline	79.67 ± 3.51 ^a	59.00 ± 5.57 ^a	19.67 ± 2.08 ^a	61.33 ± 3.06 ^{ab}
Negative control	73.67 ± 3.06 ^a	47.00 ± 5.00 ^a	18.00 ± 2.00 ^a	81.00 ± 10.00 ^c
Synbiotic yogurt	100.00 ± 3.60 ^b	51.00 ± 7.55 ^a	22.33 ± 1.53 ^a	51.33 ± 7.02 ^{ab}
Synbiotic yogurt + EPEC	114.00 ± 11.79 ^b	48.33 ± 8.74 ^a	21.33 ± 2.08 ^a	48.67 ± 6.51 ^a
Positive control	77.00 ± 7.55 ^a	49.33 ± 8.39 ^a	21.00 ± 2.64 ^a	63.67 ± 1.53 ^b
Termination on Day 15				
Negative control	59.00 ± 4.00 ^b	45.67 ± 8.14 ^c	25.67 ± 4.93 ^c	96.33 ± 5.51 ^b
Synbiotic yogurt	76.00 ± 6.08 ^c	63.67 ± 4.72 ^d	34.33 ± 1.53 ^d	54.67 ± 3.51 ^a
Synbiotic yogurt + EPEC	52.00 ± 4.58 ^b	33.67 ± 1.53 ^b	17.33 ± 3.06 ^b	128.33 ± 3.06 ^c
Positive control	5.33 ± 4.16 ^a	19.67 ± 3.06 ^a	9.33 ± 1.53 ^a	203.33 ± 8.14 ^d
Termination on Day 22				
Negative control	63.33 ± 4.04 ^{bc}	47.00 ± 1.73 ^{bc}	34.00 ± 2.64 ^b	94.00 ± 7.00 ^c
Synbiotic yogurt	68.00 ± 6.56 ^c	55.67 ± 5.86 ^d	32.67 ± 3.78 ^b	51.33 ± 4.16 ^a
Synbiotic yogurt + EPEC	53.33 ± 7.37 ^b	41.00 ± 3.60 ^b	19.67 ± 2.31 ^a	98.33 ± 5.03 ^c
Positive control	22.33 ± 2.08 ^a	22.33 ± 1.53 ^a	17.00 ± 4.58 ^a	153.00 ± 5.29 ^d
Standard yogurt	56.33 ± 4.62 ^b	52.67 ± 4.16 ^{cd}	34.67 ± 3.51 ^b	75.00 ± 4.58 ^b

Notes:

The data were analyzed statistically (by Anova and Duncan tests) in every same column and termination time. The values followed by the same letters indicated those were not significantly different ($p > 0.05$).

addition, according to Bao *et al.* (2010), *L. fermentum* had the potential probiotic characteristics and Son *et al.* (2009) said that *L. plantarum* could produce antimicrobial compounds, such as plantaricin, which was active against pathogenic bacteria. *L. plantarum* could produce lactolin which was natural antibiotic, eradicated pathogens from the fermented food, increased the number of immune system cells, and synthesized the antiviral amino acids (L-lysine) (Lee and Salminen, 2009).

Enteropathogenic bacteria that caused diarrheal attached and penetrated into the intestinal mucous membrane in order to reach and attack the enterocytes (intestinal epithelial cells) and cause a clinical infection (Rinkinen *et al.*, 2003). Janda and Abbott (2006) explained that EPEC adhered to the pattern of localized adherence (LA) where EPEC would form the micro colonies and attach firmly on the specific locations of the surface epithelial cells. Then it caused damage to the intestinal microvilli. This damage caused reduction in fluid and electrolyte absorption capacity due to the smaller of intestinal surface area. Therefore, EPEC could cause diarrheal but did not cause the weight loss in rats.

The result showed that the synbiotic yogurt could

increase the content of Cu, Zn-SOD in the liver tissue. Songisepp *et al.* (2004) mentioned that *L. fermentum* ME-3 has a high antioxidative potential shown by the total antioxidative activity (TAA) value. TAA of *L. fermentum* ME-3 was expressed as the inhibition percentage of the linolenic acid (LA) peroxidation of the sample. The TAA value of *L. fermentum* ME-3 was 26% (Songisepp *et al.*, 2004). *L. fermentum* ME-3 as a probiotic with antimicrobial and antioxidative activity was beneficial to improve the oxidative stress status of organisms that consume and could reduce the risk of infection (Mikelsaar and Zilmer, 2009). Halliwell and Gutteridge (1999) described that exposure to the organism by a mild oxidative stress could cause the increased synthesis of antioxidant defense system quickly (e.g. catalase, SOD, and glutathione peroxidase activity). This response helps to protect the cells against stronger oxidative stress and radicals attack in the following time so that the cells become resistant to the presence of the stronger free radicals. This mechanism of adaptation generally involved the gene expression changes that lead to the increased antioxidant defenses (Halliwell and Gutteridge, 1999).

In the other sources, Hartanti (2010) mentioned that probiotics could stimulate the immune system by enhancing the phagocytosis function of monocyte. The monocytes are not only invading the microbes, but also producing the cytokines (IL-6 and TNF- α) and mobilizing the body defenses in response to infection. The monocytes will produce IL-6 and TNF- α in the availability of zinc in vitro (Garina, 2009). IL-6 (interleukin-6) and TNF- α (tumor necrosis factor- α) induce heat and produce acute phase protein in liver, modulate the production of copper (Cu) and zinc (Zn), and affect metabolism (Baratawidjaja, 2006). The availability of Cu and Zn contributes to the formation or activation of Cu, Zn-SOD enzyme because the Cu, Zn-SOD requires Cu and Zn for its biological activity (Li *et al.*, 2010). Therefore, the synbiotic yogurt provided better benefits against EPEC infection compared to the treatment without synbiotic yogurt.

According to Langen and Madsen (2010), probiotics had double benefits. They modulated the intestinal microflora and reduced the oxidative stress and inflammation in hepatocytes. Peran *et al.* (2006) reported that treatment with *L. fermentum* shown the recovery from the inflammatory response in colitis rats.

The synbiotic yogurt was able to increase the content of the Cu, Zn-SOD in rats' kidney tissue. Cheng *et al.* (2006) said that the invasion of pathogenic bacteria and fungi into the host caused

the decreasing in SOD activity. Mikelsaar and Zilmer (2009) reported that *L. fermentum* could produce NO (nitric oxide). NO can induce the protection against inflammation, which can functionally activate the cellular antioxidant defense system. The application of *L. fermentum* ME-3 alleviates inflammation and OxS-related shifts in guts, based on complicated cross-talk between strain ME-3 and host cells with the integrated influence of several factors such as the ability of strain ME-3 to apply a complete glutathione system, the expression of antioxidative enzyme in strain ME-3, the production of NO by the strain, etc (Mikelsaar and Zilmer, 2009). NO itself can act as powerful antioxidant that can quickly scavenge the peroxy radical (Papas, 1999). Probiotics can also inactivate the free radicals and degrade the superoxide anion and hydrogen peroxide by enzymatic mechanism, such as NADH oxidase/peroxidase, SOD, and catalase. Probiotics have defensive mechanisms, such as modulate the mucosal immune system by blocking the proinflammatory cytokines, have antagonistic activity against pathogens by producing antibacterial compounds or inhibit the attachment of pathogenic bacteria, and enhance the protective function of epithelial cells (Sengul *et al.*, 2010). Therefore, the synbiotic yogurt which contained the probiotic *L. fermentum* 2B4, could improve the profile of Cu, Zn-SOD in liver and kidney tissues so that the synbiotic yogurt had potentially antioxidative activity. In other words, probiotics could induce the increased or decreased regulation of the immune response by maintaining the homeostatic of digestive tract (Galdeano *et al.*, 2007). Adebayo-Tayo and Onilude (2008) and Fukuda *et al.* (2010) reported that *L. fermentum* was able to produce exopolysaccharide (EPS). The EPS secreted by probiotic bacteria might reduce the oxidative stress significantly (Sengul *et al.*, 2010). According to Sengul *et al.* (2010), all antioxidant enzyme (superoxide dismutase, catalase, total glutathione, reduced glutathione, and glutathione disulfide) activities were higher in both probiotic-treated groups compared to the colitis model group ($p < 0.1$). Furthermore, EPS-producing probiotic bacteria significantly attenuate oxidative stress in experimental colitis, which may be mediated by EPS in a dose-dependent manner. The EPS was secreted by the probiotic bacteria to the cell surface and then it formed a capsule. Or it was secreted into the extracellular environment as slime. EPS can show antioxidative benefits to repair the oxidative damage of the mucosa.

Conclusion

Synbiotic yogurt had antidiarrheal properties shown by the normal appearance of feces (oval, black, and hard or soft feces) and fecal water content of the rats and was able to maintain the high content of Cu, Zn-SOD in rats liver tissue similar to the negative control group (normal rats) and could increase the content of the Cu, Zn-SOD in rats kidney tissue as much as 14.72%. In rats that experienced the EPEC intervention, the synbiotic yogurt could increase the content of Cu, Zn-SOD in rat liver tissue as much as 17.72% and kidney tissue as much as 24.96%. Thus, the synbiotic yogurt that contained the probiotic *L. fermentum* 2B4 had antioxidative properties.

Acknowledgements

The authors would like to thank to the Directorate of Research and Community Service, Department of National Education–Republic of Indonesia which has provided the research fund through the Competency Grant, Contract Number: 375/SP2H/PL/Dit.Litabmas/IV/2011, on behalf of Mr. Made Astawan dated April 14, 2011 and to Mr. Rachmat Widyanto for his helpful script correction.

References

- Adebayo-tayo, B. C. and Onilude, A. A. 2008. Screening of lactic acid bacteria strains isolated from some Nigerian fermented foods for EPS production. *World Applied Sciences Journal* 4: 741-747.
- Bacteriological Analytical Manual (BAM). 2001. BAM: Aerobic Plate Count. USA.
- Bao, Y., Zhang, Y., Zhang, Y., Liu, Y., Wang, S., Dong, X., Wang, Y. and Zhang, H. 2010. Screening of potential probiotic properties of *Lactobacillus fermentum* isolated from traditional dairy products. *Food Control Journal* 21: 695-701.
- Baratawidjaja, K. G. 2006. Basic Immunology. Seventh Edition. Jakarta: Faculty of Medicine Publisher, University of Indonesia.
- Budiarti, S. 1997. Attachment to the Hep-2 cells and diversity of *Escherichia coli* serotype O isolates enteropathogenic Indonesia. *Jurnal Berkala Ilmu Kedokteran* 29: 105-110.
- Cheng, W., Tung, Y. H., Liu, C. H. and Chen, J. C. 2006. Molecular cloning and characterization of copper/zinc superoxide dismutase (Cu, Zn-SOD) from the giant freshwater prawn *Macrobrachium rosenbergii*. *Fish and Shellfish Immunology* 21: 102-112.
- Davidson, P. M., Parish, M. E., Palou, E. and Vigil, A. L. M. 2005. Methods for activity assay and evaluation of results, p. 659-680. Boca Raton: CRC Press.
- Fukuda, K., Shi, T., Nagami, K., Leo, F., Nakamura, T., Yasuda, K., Senda, A., Motoshima H. and Urashima, T. 2010. Effects of carbohydrate source on physicochemical properties of the exopolysaccharide produced by *Lactobacillus fermentum* TDS030603 in a chemically defined medium. *Carbohydrate Polymers* 79: 1040-1045.
- Galdeano, C.M., de Moreno de Le Blanc, A., Vinderola, G., Bonet, M. E. B. and Perdigon, G. 2007. Proposed model: mechanisms of immune modulation induced by probiotic bacteria. *American Society for Microbiology* 14: 485-492.
- Garina, L. A. 2009. Plasma zinc levels and interleukin-12 in children 6-14 years old in malaria endemic areas. Semarang: Diponegoro University, thesis.
- Halliwell, B. and Gutteridge, J. M. C. 1999. Free radicals in biology and medicine. 3rd edn. New York: Oxford University Press, Inc.
- Hartanti, A. W. 2010. Evaluation of antidiarrheal activity of *Lactobacillus* isolates from breast milk. Bogor: Bogor Agricultural University, MSc thesis.
- Janda, J. M. and Abbott, S. L. 2006. The Enterobacteria. 2nd edn. Washington: ASM Press.
- Kiernan, J. A. 1990. Histological and histochemical methods: Theory and practice. 2nd edn. Oxford: Pergamon Press.
- Langen, M. L. V. and Madsen, K. 2010. Pre- and probiotics in liver health and function, p. 97-116. London: Academic Press.
- Lee, Y. K. and Salminen, S. 2009. Handbook of probiotics and prebiotics. 2nd edn. New Jersey: John Wiley and Sons, Inc.
- Li, C., Sun, H., Chen, A., Ning, X., Wu, H., Qin, S., Xue, Q. and Zhao, J. 2010. Identification and characterization of an intracellular Cu, Zn-superoxide dismutase (icCu/Zn-SOD) gene from clam *Venerupis philippinarum*. *Fish and Shellfish Immunology* 28: 499-503.
- Loo, J. V. 2006. Inulin-type fructans as prebiotics. In: Gibson, G. R. and Rastall, R. A. (Eds.). *Prebiotics: Development and Application*, p. 57-100. Chichester: John Wiley and Sons, Ltd.
- Mikelsaar, M. and Zilmer, M. 2009. *Lactobacillus fermentum* ME-3 – an antimicrobial and antioxidative probiotic. *Microbial Ecology in Health and Disease* 21: 1-27.
- Papas, A. M. 1999. Antioxidant status of the digesta and colon cancer: is there a direct link?, p. 431-445. Boca Raton: CRC Press.
- Peran, L., Camuesco, D., Comalada, M., Nieto, A., Concha, A., Adrio, J. L., Olivares, M., Xaus, J., Zarzuelo, A. and Galvez, J. 2006. *Lactobacillus fermentum*, a probiotic capable to release glutathione, prevents colonic inflammation in the TNBS model of rat colitis. *International Journal Colorectal Disease* 21: 737-746.
- Rinkinen, M., Jalava, K., Westermarck, E., Salminen, S. and Ouweland, A. C. 2003. Interaction between probiotic lactic acid bacteria and canine enteric pathogens: a risk factor for intestinal *Enterococcus faecium* colonization?. *Veterinary Microbiology* 92: 111-119.
- Sengul, N., Isik, S., Aslim, B., Ucar, G. and Demirbag, A. E. 2010. The effect of exopolysaccharide-

- producing probiotic strains on gut oxidative damage in experimental colitis. *Digestive Disease and Science* 56 (3): 707-714.
- Songisepp, E., Kullisaar, T., Hutt, P., Elias, P., Brilene, T., Zilmer, M. and Mikelsaar, M. 2004. A new probiotic cheese with antioxidative and antimicrobial activity. *Journal Dairy Science* 87: 2017-2023.
- Son, V. M., Chang, C. C., Wu, M. C., Guu, Y. K., Chiu, C. H. and Cheng, W. 2009. Dietary administration of the probiotic, *Lactobacillus plantarum*, enhanced the growth, innate immune responses, and disease resistance of the grouper *Epinephelus coioides*. *Fish and Shellfish Immunology* 2: 691-698.
- Wresdiyati, T., Mamba, K., Adnyane, I. K. M. and Aisyah, U. S. 2002. The effect of stress condition on the intracellular antioxidant copper, zinc-superoxide dismutase (Cu, Zn-SOD) in the rat kidney: an immune histochemical study. *Hayati* 9: 85-88.
- Wrolstad, R. E., Decker, E. A., Schwartz, S. J. and Sporns, P. 2005. *Handbook of Food Analytical Chemistry*. New Jersey: John Wiley and Sons, Inc.