

## Pathological lesions survey and economic loss for male cattle slaughtered at Ismailia abattoir

\*Ahmed A. M., Ismail S. A.S. and <sup>1</sup>Dessouki A. A.

*Department of Food Hygiene, <sup>1</sup>Department of Pathology, Faculty of Veterinary Medicine, Suez Canal University, Ismailia, Egypt*

### Article history

Received: 30 July 2012

Received in revised form:

12 October 2012

Accepted: 15 October 2012

### Abstract

The study was a retrospective abattoir survey, undertaken for a period of one full year at the main traditional abattoir of Ismailia city, Egypt. During the survey, 9880 male cattle were slaughtered and inspected. As a result of postmortem inspections, 8 (0.10%) carcasses were totally condemned and 1456 (14.7%) organs had pathological lesions. Of the 1456 edible organs had pathological lesions; the sum of 1216 Kg was either totally or partially condemned. Based on weight of annual condemned organs, the estimated annual loss was 36480 Egyptian Pound. The gross pathological lesions detected in edible organs were in 117 of heart (8%), in 310 kidneys (21.3%), in 649 lunges (44.6%), in 260 livers (17.9%), and in 120 spleens (8.2%). The present study provides baseline data for the future monitoring of clean meat production in Ismailia abattoir. The condemnation of edible organs represents a significant economic loss to traders and livestock industry.

### Keywords

*Inspection  
season  
Egypt*

© All Rights Reserved

### Introduction

Meat is considered as a food of choice due to its great nutritional value. Meat is well known as an excellent good biological values protein and is a main source of many nutrients, especially B vitamins, iron and zinc. Cattle are considered the main sources of animal protein for the population of Egypt, where the human demand for animal proteins is annually increasing. The results of meat inspection at slaughterhouses with appropriate trends indicate possible risks due to unsafe meat obtained from cattle carcasses at the slaughterhouses. Such risks are eliminated by strict veterinary inspection of animals prior to slaughter as well as of meat and parenchymatous organs after slaughter. Slaughterhouses provide an excellent opportunity for detecting pathological lesions of both economic and public health importance (Vecerck *et al.*, 2003).

Meat production in Egypt is governed by the legislation No. 517, Egyptian Guidelines for Cattle Inspection (EOS, 1986). The legislation classifies bovine carcasses into the categories of capable for human consumption (edible), capable for processing (conditionally edible), and condemned based on the results obtained from the ante-mortem and post-mortem inspection. Previous works (Maxwell, 2005;

Ahmedullah *et al.*, 2007; Mellau *et al.*, 2010; Alawa *et al.*, 2011) had focused on pathological findings in bovine carcasses which are usually related to infectious diseases of cattle.

Slaughterhouses provide the opportunity for detecting diseases of both economic and public health importance (Raji *et al.*, 2010). Numerous abattoir surveys of bovine pathological conditions have been conducted to investigate macroscopic and microscopic abnormalities in different countries (El-Dakhly *et al.*, 2007; Mwabonimana, 2008; Belkhiri *et al.*, 2009; Raji *et al.*, 2010; Alawa *et al.*, 2011). Records of ante-mortem and post-mortem inspections are useful epidemiological data for the evaluation of diseases at farm level and verify the efficacy of prophylactic and therapeutic interventions (Ogunrinde, 1980; Anita, 1982).

Generally in Egypt, the detection rate of pathological lesions may influenced by season when slaughtering was elevated during religious feasts and socio-cultural ceremonies. In Ismailia Governorate, thousands of slaughtered animal are processed as meat for human consumption each year. However, no study has been carried out among bovine species brought in for slaughter in Ismailia city to determine the prevalence of the pathological lesions affecting the carcasses and organs.

\*Corresponding author.

Email: [ameawad@yahoo.com](mailto:ameawad@yahoo.com)

Therefore, the current study was focused on the results of cattle inspections within the processes of antemortem and postmortem inspection in the main abattoir of Ismailia Governorate which is located Abo-Atwa district. The main aim was to compare the figures from four seasons started from spring season followed by winter, autumn and summer seasons. Pathological technique were used in certain condition for confirmation the specific lesions. Finally based on the data obtained this way the potential risk of unsafe meat and food-borne diseases originating from beef meat and organs was assessed.

## Materials and Methods

### *Study population*

The study animals comprised male cattle presented for slaughter from different localities in the Ismailia Abattoir. A total of 9880 cattle were slaughtered over one year and examined following ante-mortem and post-mortem inspection procedure. The prevalence of the gross lesions was collected on a four seasonal basis (autumn, winter, spring and summer). It was not possible to get the exact records on breed, gender, weight and age for each slaughtered animals during the study period due to poor recording systems at the Ismailia abattoir.

### *Pre and post slaughter inspection*

Meat inspection was carried out at the Ismailia abattoir by trained veterinarians under close supervision of local authority. All animals presented for slaughter were physically observed before or shortly prior to slaughter. Inspection of the animals was made while at rest or in motion for any obvious sign of disease. Post-slaughter examination involved visual examination of carcasses and organs with keen attention being directed to livers, lungs, hearts, gastrointestinal tract and skin through palpation and incision of suspected organs.

### *Macroscopic and microscopic pathological lesions*

The records of the organ lesion(s) that observed and condemned were noted by meat inspector based on Egyptian Guidelines for Inspection of Cattle (EOS, 1986). All lesions were collected, determined the average weight and imaged by digital camera. Each lesion was fixed in formalin 10%, and then the section was prepared by the paraffin embedding technique (Luna, 1968). Paraffin section was cut at 5 micrometer in thickness and stained with haematoxyline and eosin stain. Stained section was microscopically examined and histological findings were recorded.

### *Economic loss assessment*

The direct economic loss from organs condemnation (Kg) was assessed by considering the overall average weight of the organs and the retail market price of an average organs express by Egyptian pound.

### *Statistical analysis*

Collected post-mortem/meat inspection records were entered, edited, validated and performed. The occurrence of pathological abnormalities was calculated. The figures of lesions showed in colored imaged. Seasonal pattern over the full study period was investigated by  $\chi^2$ -test using Microsoft excel version 2003. Differences were compared between seasons, a P-value less than 0.05 was considered statistically significant.

## Results and Discussion

### *Cattle slaughtered, condemned and economic loss*

In the study period, 9880 male cattle were slaughtered in the Ismailia abattoir. Based on seasons, 2502 (25.2%), 1737 (17.5%), 1950 (19.7%) and 3691 (37.6%) male cattle were slaughtered in autumn, winter, spring and summer respectively (table 1.). Autumn and summer seasons were the highest season in number of slaughtered animal in Ismailia abattoir. According to the results of the statistical analysis, significant difference ( $P < 0.05$ ) was observed in number of slaughter cattle between summer season and other seasons. This may due to the site of Ismailia as a tourist city that attracts many people during summer season, subsequently increased in their population and meat demand.

There was no animal condemned as result of antemortem inspection allover the study period. As a result of postmortem inspections, 8 (0.10%) carcasses were condemned and 1456 (14.7%) organs had pathological lesions. Feeding, breed and management of cattle may be associated with the presence or absence of pathological lesions and could cause carcass condemnation during the inspection process. It was shown that the proportion of cattle showing pathological lesions differ between countries (Mwabonimana 2008; Belkhiri *et al.*, 2009; Raji *et al.*, 2010; Alawa *et al.*, 2011). The slaughterhouse and its regulations, represents a key control point of livestock production chain (Ogunrinde, 1980; Antia, 1982). Results of meat inspection of slaughter animal is too importance for animal health control system (Fries, 1994).

Of the 1456 edible organs had pathological lesions; the sum of 1216 Kg was either totally or partially condemned. The weight of condemned organs from

Table 1. Seasonal slaughter, meat production and condemnation for cattle in Ismailia abattoir

Season	Number Slaughtered		Condemned				Pathological Lesions				Economic Loss
			Ante mortem		Postmortem		Organs Number		Organs Weight (Kg)		
	No.	F	No.	F	No.	F	No.	F	No.	F	*Egyptian Pound
Autumn	2502 <sup>a</sup>	25.2	0	0	2	25	421	28.9	291 <sup>a</sup>	23.9	8730
Winter	1737 <sup>a</sup>	17.5	0	0	1	12.5	251	17.2	203 <sup>a</sup>	16.7	6090
Spring	1950 <sup>a</sup>	19.7	0	0	1	12.5	381	26.2	352 <sup>b</sup>	29.0	10560
Summer	3691 <sup>b</sup>	37.6	0	0	4	50	403	27.7	370 <sup>b</sup>	30.4	11100
Total	9880	100	0	0	**8	100	1456	100	1216	100	36480

\*Average market price for organs was 30 Egyptian Pound

F means frequency

\*\*The percentage of post-mortem condemnation based on total animal slaughter is 0.1%

Means with the same litter in the same column were not different (P > 0.05)

male cattle were 291 (23.9%), 203 (16.7%), 352 (29.0%) and 370 (30.4%) kg during autumn, winter, spring and summer respectively. The significance high weight (P < 0.05) of condemned organs was observed in spring and summer seasons in compared to autumn and winter seasons. Abattoir is considered as the biggest laboratory on the earth (Greacy *et al.*, 1999). Many authors have studied animal health based on findings from slaughterhouses within the framework of veterinary inspection of slaughter animals and meat. Animal health is the parameter which is most important for the classification of meat and organs of food animals with regard to their capability to serve for human consumption.

Table 2. Gross pathological lesions in cattle organs at Ismailia abattoir

Organs	Autumn		Winter		Spring		Summer		Total No. (F)
	No.	F	No.	F	No.	F	No.	F	
<b>Heart Lesions</b>									117 (8.0)
Traumatic pericarditis	2	0.5	1	0.4	2	0.5	2	0.5	
Heart adhesion	29	6.9	17	6.8	24	6.2	40	9.9	
<b>Kidney Lesions</b>									310 (21.3)
Kidney crystal	34	8.1	19	7.6	24	6.2	23	5.7	
Hydronephrosis	13	3.1	1	0.4	6	1.6	3	0.7	
White spot	27	6.4	17	6.8	30	7.9	23	5.7	
Fibrosis	14	3.3	11	4.4	2	0.5	11	2.8	
Pyelonephritis	17	4.1	10	3.9	14	3.7	11	2.8	
<b>Lung Lesions</b>									649 (44.6)
Congestion	25	5.9	24	9.6	30	7.9	15	3.7	
Abscesses	41	9.7	25	9.9	36	9.5	35	8.7	
Pneumonia	114	27.1	69	27.6	97	25.5	138	34.2	
<b>Liver Lesions</b>									260 (17.9)
Abscesses	42	9.9	35	13.9	54	14.2	50	12.4	
Cirrhosis	23	5.5	7	2.8	22	5.8	27	6.7	
<b>Spleen Lesions</b>									120 (8.2)
Splenomegaly	40	9.5	15	5.9	40	10.5	25	6.2	
<b>Total</b>	421	100	251	100	381	100	403	100	1456 (100)

\*Organs appear in table ranked in letter order

Table 3. Frequency distribution of pathological lesions in edible organs of cattle

Organs	Lesions	
	F	%
<b>Heart Lesions</b>		
Traumatic pericarditis	7	0.5
Heart adhesion	110	7.5
<b>Kidney Lesions</b>		
Kidney crystal	100	6.9
Hydronephrosis	23	1.6
White spot	97	6.7
Fibrosis	38	2.6
Pyelonephritis	52	3.6
<b>Lung Lesions</b>		
Congestion	94	6.5
Abscesses	137	9.4
Pneumonia	418	28.7
<b>Liver Lesions</b>		
Abscesses	181	12.4
Cirrhosis	79	5.4
<b>Spleen Lesions</b>		
Splenomegaly	120	8.2
<b>Total</b>	1456	100

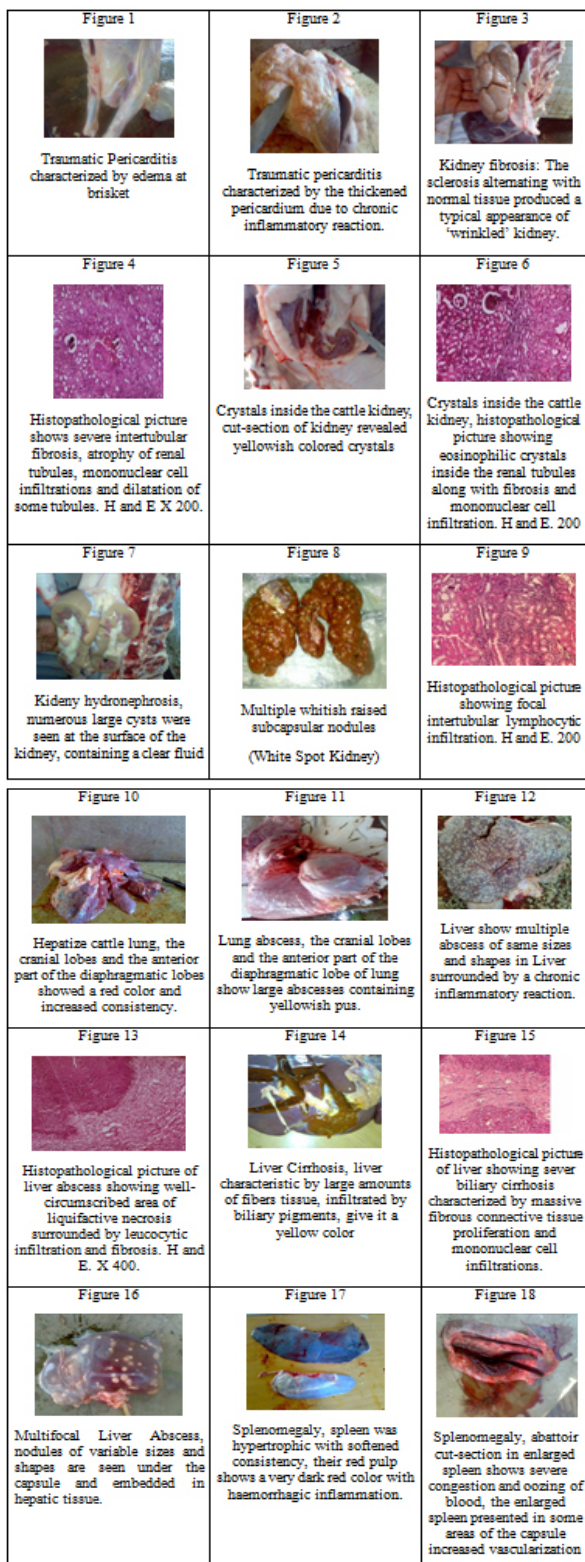
The direct economic loss results from organs condemnation as the result of pathological lesions was calculated based on 30 Egyptian Pound as the average retail price of edible organs per kilogram in Ismailia city. The estimated annual loss from total weight of organ condemnation was 36480 Egyptian Pound. Spring and summer season represent the higher economic loss in compared with other season. Pathological lesions constitute a serious and major problem as well as for breeders than for veterinarians, because of the major economic losses they cause, and the expenses of the care and preventions that they generate.

*Pathological lesions*

Localized pathological conditions in the cattle are requiring more serious attention inside slaughter hall such as total or partial condemnation were applied. The result obtained in table 2 showed the gross pathological lesions in cattle organs at Ismailia abattoir. Among the 9880 slaughtered cattle, 1456 organs were grossly affected with pathological lesions. Of the 1456 pathological cases, 421, 251, 381 and 403 pathological cases recorded in autumn, winter, spring and summer seasons respectively. Irrespective of seasonal variations, almost even distributions of pathological lesions were occurring during the all seasons. The gross pathological lesions detected in edible organs were in 117 of heart (8%), in 310 kidneys (21.3%), in 649 lunges (44.6%), in 260 livers (17.9%), and in 120 spleens (8.2%). Pathology of the slaughterhouse is different from the pathology that is seen in a diagnostic laboratory. A veterinarian uses the same skills and knowledge base of a necropsy laboratory to arrive at a diagnostic at slaughter (Edwards *et al.*, 1997).

Pathological conditions for farmed animals are caused by a combination of infectious agents and predisposing factors (Blood *et al.*, 1979; Eddy *et al.*, 1992). Under rearing conditions, most bovine





livestock harbor some disease conditions without clinical manifestation and during abattoir ante-mortem inspections, hundreds of such animals are passed for slaughter (Okoli *et al.*, 2002). The results presented by Kofor *et al.* (2001), Schuh *et al.* (2000), Grest *et al.* (1997) and Lis (1999) indicate that pathological changes are found in significant numbers of organs of food animals inspected.

### Heart lesions

In this study, the lowest relative numbers of pathological findings in Ismailia abattoir were recorded in heart (117 cases). Traumatic pericarditis was encountered in 7 (0.5%) and Heart adhesion in 110 (7.5 %). Figure (1) shows traumatic pericarditis observed, bull shows apathetic and. edema was observed at the entry of the thorax as well as in the subglossal region. Figure (2) shows traumatic pericarditis characterized by edema at brisket. Figure (3) shows traumatic pericarditis characterized by the thickened pericardium due to chronic inflammatory reaction whose traumatic nature is clearly visible in the image. Figure (4) shows heart adhesion as result of traumatic pericarditis, heart shows multiple haemorrhages and congestion of various sizes and shapes, making it look unpleasant. Traumatic Reticuloperitonitis is a relatively, common disease in adult cattle caused by the ingestion and migration of foreign bodies in the reticulum. Swallowed metallic objects, such as nails or pieces of wire, and fall directly into the reticulum or pass into the rumen and clinical are subsequently carried over the ruminoreticular fold into the cranioventral part of the reticulum. Similar results were obtained by Hajjghramani and Ghane (2010).

### Kidney lesions

A total of 310 pathological findings in kidney were reported in slaughtered animal at Ismailia abattoir. Kidney crystals was encountered in 100 (6.9%), hydronephrosis in 23 (1.6%), white spots in 97 (6.7%), fibrosis in 38 (2.6%) and pyelonephritis in 52 (3.6%) of the condemned kidney. Figure (5) shows atrophy in cattle kidney: nodular and indurated. Kidney shows a dark brown color interrupted in a few lobes by areas of whitish tissue, visible through the capsule. The sclerosis alternating with normal tissue produced a typical appearance of 'wrinkled' kidney. White strands in the thin cortical tissue can be seen in the cut surface of the organ. The results in figure (6) confirmed the obtained results by histopathological picture showing severe intertubular fibrosis, atrophy of renal tubules, mononuclear cell infiltrations between some tubules.

Figure (7) shows cut-section of cattle kidney revealed that observed yellowish colored crystals. Figure(8) confirmed the finding with histopathological picture showing eosinophilic crystals inside the renal tubules along with fibrosis and mononuclear cell infiltration. Crystal kidney were leading to narrowing of vascular channels, nephrons deprived of an adequate blood supply may show atrophic change and cirrhosis (Tavassoly, 2003).

Figure (9) shows hydronephrosis observed in kidney at Ismailia abattoir. Numerous large cysts were seen at the surface of the kidney, containing a clear fluid. This change was due to mechanical obstruction of the urethra, with consequent retention of urine. Figure (10) shows pyelonephritis observed in Ismailia abattoir. Kidney was hypertrophic and showed under the capsule (removal of which was difficult) whitish-yellow patches of variable diameter, some occupying an entire lobe. Small irregular retractions were noticed at the surface of some lobes corresponding to a retraction of fibrous tissue which replaced a considerable amount of the normal parenchyma.

Figure (11) shows multiple whitish raised subcapsular nodules (White Spotted Kidney). The finding was confirmed by figure (12) which shows histopathological picture showing focal intertubular lymphocytic infiltration. White spotted kidney is a focal, non suppurative interstitial nephritis in bovine. These spots are aggregation of leukocytes in interstitial of kidney and occasionally these spots may bulge from surface of kidney. Similar results were obtained by Tavassoly, (2003).

#### Lung lesions

Lungs are the most exposed organs to different aggressions because of their anatomical and histological particularities. In the current study, the most recorded pathological findings in slaughtered animal at Ismailia abattoir were the lung lesions (649 lesions). Pneumonia is of importance in all livestock production due to harsh weather conditions during the dry season and verminous pneumonia during the rainy season which often resulted in bovine mortality (Isoun and Mann, 1977). Seasons had effect on the prevalence of bovine lung diseases (Maxwell, 2005).

Grossly lung lesion were 94 cases of lung congestion (6.5%), 137 lung abscesses (9.4%) and 418 cases of pneumonia (28.7%). Pneumonia was the leading cause of lung condemnation in all slaughtered animal species. In this study, pneumonia was recorded during the rainy and dry seasons and thus agrees with Halle (1998) who observed that both seasons exacerbate this condition in livestock. Figure (13) shows hepatize cattle lung, the cranial lobes and the anterior part of the diaphragmatic lobes showed a red color and increased consistency similar to the liver. The described characteristics correspond to the red consolidation (hepatization) stage of the lobar pneumonia.

Figure (14) lung showing bluish discoloration (congestion) in lung observed in Ismailia abattoir. Pulmonary congestion is initiated by an influx of blood in the lung due to the obstruction of the

pulmonary vessels. It is sometimes followed by pulmonary edema that when the intravascular liquid spills in parenchyma and alveoli (Blood and Henderson, 1976). Figure (15) lung abscess observed in Ismailia abattoir the cranial lobes and the anterior part of the diaphragmatic lobe were showing large abscesses containing yellowish pus. The current study demonstrates that lung diseases and lesions represent a serious problem and may continue to be a drawback to livestock industry and may pose health risks to meat consumers from contrasting zoonotic diseases in Ismailia. Similar results were obtained by Atsanda and Agbede, (1999), Maxwell (2005), Mellau *et al.*, (2010) and Raji *et al.* (2010).

#### Liver lesions

A total of 260 pathological findings in liver were reported in slaughtered animal at Ismailia abattoir. The most recorded liver lesions were abscess 181 (12.4%) followed by liver cirrhosis 79 (5.4%). Liver abscess are bacterial based and the infection occurs due to migrating intestinal parasites which pre- optimize the conditions for a secondary bacterial infection and commonly associated with liver enlargement (Rosa *et al.*, 1989).

Results of macroscopic lesions of cattle liver shows multiple numerous abscesses of same sizes and shapes in Liver surrounded by a chronic inflammatory reaction. The accidental opening of one of them showed pasty yellow green pus (Figure 16). The finding was confirmed by histopathological picture of such lesion that shows well-circumscribed area of liquifactive necrosis surrounded by leucocytic infiltration and fibrosis (Figure 17). Cirrhosis in Liver of cattle characteristic by their profile has considerable changed due to the multiple light brown nodules, prominent under the capsule, in between the nodules large amounts of fibers tissue, infiltrated by biliary pigments, give it a yellow color (Figure 18, 19, 20).

Similar results were obtained by Maxwell (2005), El-Dakhly *et al.*, (2007) and Raji *et al.*, (2010). Affections of the liver in meat-producing animals constitute a major factor that reduce our national income, either directly through condemnation of the affected livers, or indirectly by their effect on the animal growth and so its meat production (Eid *et al.*, 1998).

#### Spleen lesions

A total of 120 pathological findings in spleen were reported in slaughtered animal at Ismailia abattoir. The image in figure (21) shows severe enlargement of cattle spleen (Splenomegaly) characteristics by

hypertrophic with softened consistency. The red pulp shows a very dark red color with haemorrhagic inflammation. Figure (22) cut-section shows severe congestion in enlarged spleen. Blood oozing presented in some areas of the capsule. The parenchyma equally abnormal with bright red areas alternating with dark red hemorrhagic ones. All inspected spleen lesions (100%) shown slight yellow discoloration, markedly enlarged (Splenomegaly), and dark red in color and bulged from the cut surface (Congestion). Gracey *et al.*, (1999) describe the same lesion in spleen in case of cattle infestation with blood parasites. The normal spleen weight for adult bovine is 0.17% of body weight. While in case of abnormalities, spleen weight is 0.6% of body weight (Fadraga *et al.*, 1991).

In conclusion, abattoir records show a wide spectrum and types of pathological lesions that occurring in traditional livestock herds. The present study provides baseline data for the future monitoring of clean meat production in the Ismailia abattoir. The condemnation of edible organs represents a significant economic loss to traders and the livestock industry.

### Acknowledgements

The authors are thankful to Prof. Dr. Ahmed M. Shoieb, BVSc, Ph D., Diplomate ACVP, Veterinary Pathologist Pfizer Ltd IPC 330 for his helps, comments and technical assistance. Also great thanks for to thank Dr. Ahmed Al-Garhy, Vice Director of Ismailia city abattoir, Egypt for co-operation, his technical assistance during samples and data collection

### References

- Ahmedullah, F., Akbor, M., Haider, G. Hossain, M., Khan, A., Hossain, M. and Shanta, I. 2007. Pathological investigation of liver of the slaughtered buffaloes in barisal district. *Bangladesh Journal Veterinary Medicine* 5(1 and 2): 81-85.
- Alawa, C.B., Etukudo-Joseph, I. and Alawa, J.N. 2011. A 6-year survey of pathological conditions of slaughtered animals at Zango abattoir in Zaria, Kaduna State, Nigeria. *Tropical Animal Health Production* 43(1): 127-131.
- Antia RE. 1982. Survey of abattoir data in Southern Nigeria. *Tropical Animal Health Production*, 14:2.
- Atsanda, N.N. and Agbede, S.A. 1999. Survey for brucellosis, tuberculosis and cysticercosis in cattle slaughtered in Ibadan and Maiduguri abattoirs. *Nigeria Veterinary Journal*, 21, 1: 61 – 65.
- Belkhir, M.; Tlidjane, M.; Benhathat, Y. and Meziane, T. 2009. Histopathological study and pulmonary classification of bovine lesions. *African Journal of Agricultural Research* 4(7): 584-591.
- Blood, D.C., Handerson, J.A. and Radostits, O.M. 1979. *Veterinary Medicine*, 5<sup>th</sup> ed., Bailliere Tindall limited, London, pp. 234-238.
- Eddy, R.G., Boy, B.H., Blower, R.W. and Andrew, A.H. 1992. *Bovine medicine diseases and husbandry of cattle*. 1<sup>st</sup> Ed., Black well Scientific Publication, Melbourne, pp.669-670.
- Eid, R.A., El-Mahdy, M.M., Hamouda, M.A. and Fatma, M. Darwish 1998. Some studies on parasitic liver affections of camels in Egypt. *Assiut Veterinary Medicine Journal* 38: 121 – 137.
- El-Dakhly, K.M., Hassan, W.H. and Lotfy, H.S. 2007. Some parasitic and bacterial causes of liver affections in ruminants. 5<sup>th</sup> Scientific Conference, BS. *Veterinary Medicine Journal* 2: 62-68.
- Fadraga, A., Cordoves, M. and Puentes, T., 1991. Circulation of antibodies to haemoparasites in cattle (*Bos Taurus*) of high genetics value in Cuba. *Rev. Cub-de-Cien. Veterinarias* 22: 249-255.
- Fries, R. 1994. Meat inspection findings – a mirror of animal health. *Tieartzl Umsch* 49: 642-647.
- Gracey, J.F., Collins, D.S. and Huey, R.J. 1999. *Meat Hygiene*. 10<sup>th</sup> ed., W.B. Saunders Co. Ltd., London.
- Grest P., Keller H., Sydler T. and Pospischil A. 1997. The prevalence of lung lesions on pigs at slaughter in Switzerland. *Schweizerland Archives Tierh* 139: 500-506.
- Hajjigharamani, S and Ghane, M. 2010. Traumatic Reticuloperitonitis in Cattle of Khorramabad (Center of Lorestan Provenience, West of Iran). *Global Veterinaria* 5(2): 135-139.
- Halle, P.D. 1998. Status of bovine tuberculosis in Adamawa State, Nigeria. Pages 73 – 76. In: *Proceeding of the Silver Anniversary Conference of the Nigeria Society for Animal Production (NSAP)*, Abeokuta, Nigeria.
- Isoun, T.T. and Mann, E.D. 1977. A stomatitis and pneumoenteritis complex of sheep in Nigeria. *Bulletin of Epizootiology of Diseases in Africa* 20: 167 – 172.
- Kofer J., Kutschera G. and Fuchs K. 2001. Monitoring of animal health at abattoirs. *Fleischwirtschaft* 81: 107-111.
- Law 517, 1986. Slaughter animals and meat trade. Ministry of Agriculture, Egyptian Gazette, No. 257.
- Lis H. 1999. An evaluation of veterinary inspection of slaughtered animals and meat in Poland between 1987-1997. *Medicine Veterinary* 55: 243-246.
- Luna, L.G. 1968. *Manual of histologic staining methods of the Armed Forces Institute of Pathology*. 3<sup>rd</sup> ed. New York: McGraw-Hill.
- Maxwell, O. 2005. Pathological conditions of condemned bovine lungs from abattoirs in Akwa Ibom State, Nigeria. *Animal Research International* 2: 314 – 318.
- Mellau, L.S.B., Nonga, H.E. and Karimuribo, E.D. 2010. A slaughterhouse survey of lung lesions in slaughtered stocks at Arusha, Tanzania. *Preventive Veterinary Medicine* 97: 77-82.
- Mwabonimana, M.F. 2008. Cattle liver condemnation at Arusha meat company Ltd, Tanzania; causes and its financial implication. Master Thesis, Preventive Agriculture Morogoro, Tanzania.
- Ogunrinda, A. 1980. Economic importance of bovine Fascioliasis in Nigeria. *Tropical Animal Health*



Production 12: 2.

- Okoli, I.C., Nwokeocha, J.R., Okoli, C.G. and Ogundu U.E. 2002. Prevalence of fascioliasis and oesophagostomosis among slaughtered animals in Imo State, Nigeria and their correlation with emaciation diagnosis at ante-mortem. *Tropical Veterinarian* 20(3): 139 – 148.
- Raji, M.A., Salami, S.O. and Ameh, J.A. 2010. Pathological conditions and lesions observed in slaughtered cattle in Zaria abattoir. *Journal of Clinical Pathology and Forensic Medicine* 1( 2):. 9 – 12.
- Rosa, J.S., Johnson, E.H., Alves, F.S and Santos, L.F. 1989. A retrospective study of hepatic abscesses in goats: Pathological and microbiological findings. *British Veterinary Journal* 145: 73-76.
- Schuh M., Kofer J. and Fuchs K. 2000. Installation of an information feedback system for control of animal health – frequency and economical effects of organ lesions in slaughter pigs. *Wien. Tierartztl Monat* 87: 40–48.
- Tavassoly, A. 2003. Pathological Study of Renal Lesions in the Condemned Bovine Kidneys in Ziaran Slaughterhouse. *Archives Razi Institute* 55: 97-104
- Vecerck, V., Kozak, A., Malena, M., Tremlova, B. and Chloupek, P. 2003. Veterinary meat inspection of bovine carcasses in the Czech Republic during the period of 1995–2002. *Veterinary Medicine Czech*, 48, 7: 183–189.